

Journal

CALIFORNIA DENTAL ASSOCIATION

January 2016

cda

Periodontics and
Oral-Systemic Relationships

Atypical Presentation
of Zoster

Leadership Trajectories
of U.S. Dentists



DEPARTMENTS

- 5 The Editor/My Microbiome and Me
- 7 Impressions
- 49 RM Matters/Top Seven Data Breach Considerations
- 55 Regulatory Compliance/HIPAA Security Rule Technical Safeguards
- 59 Periscope
- 64 Tech Trends
- 65 Dr. Bob/Protest Now



FEATURES

- 17 UCSF Protocol for Caries Arrest Using Silver Diamine Fluoride: Rationale, Indications and Consent
This paper presents a systematic review, clinical indications, clinical protocol and consent procedure to guide application for caries arrest treatment using silver diamine fluoride.
 Jeremy A. Horst, DDS, PhD; Hellene Ellenikiotis, DDS; and Peter L. Milgrom, DDS
- 29 Periodontics and Oral-Systemic Relationships: Diabetes
It has been proposed that periodontal disease is a risk factor for systemic diseases. This paper explores its relationship to diabetes.
 Alison Glascoe, DDS, MS; Ronald Brown, DDS, MS; Grace Robinson, DDS; and Kassahun Hailu, DDS
- 35 Atypical Presentation of Zoster Mimicking Headache and Temporomandibular Disorder: A Case Report
This article reports on a case of trigeminal herpes zoster, which presented as sudden onset headache and acute temporomandibular pain in the prodromal phase.
 Mohammad Reza Zarei, DDS, MSc, and Goli Chamani, DDS, MSc
- 39 A National Survey of Positional Leadership Trajectories of U.S. Dentists
This paper extends the nascent work in understanding leadership among dentists.
 David Chambers, EdM, MBA, PhD



SPIKE

UCSF Protocol for Caries Arrest Using Silver Diamine Fluoride: Rationale, Indications and Consent

Jeremy A. Horst, DDS, PhD; Hellene Ellenikiotis, DDS; and Peter L. Milgrom, DDS

ABSTRACT The Food and Drug Administration recently cleared silver diamine fluoride for reducing tooth sensitivity. Clinical trials document arrest and prevention of dental caries by silver diamine fluoride. This off-label use is now permissible and appropriate under U.S. law. A CDT code was approved for caries arresting medicaments for 2016 to facilitate documentation and billing. We present a systematic review, clinical indications, clinical protocol and consent procedure to guide application for caries arrest treatment.

AUTHORS

Jeremy A. Horst, DDS, PhD, is a fellow at the University of California, San Francisco, School of Dentistry studying the bacteria that cause cavities, a pediatric dentist at Alameda Pediatric Dentistry and co-founder and CSO at OraViz.
Conflict of Interest
Disclosure: Dr. Horst is co-founder and CSO at OraViz.

Hellene Ellenikiotis, DDS, is a resident in the University of California, San Francisco, general practice residency and a recent graduate of the University of California, San Francisco School of Dentistry.
Conflict of Interest
Disclosure: None reported.

Peter L. Milgrom, DDS, is a professor of dental public health sciences and pediatric dentistry and director of the Northwest Center to Reduce Oral Health Disparities at the University of Washington in Seattle.
Conflict of Interest
Disclosure: Dr. Milgrom is a principal in ADP Silver Dental Arrest LLC, which licenses permission to market Advantage Arrest to Elevate Oral Care LLC.

Until now, no option for the treatment of dental caries in the U.S. besides restorative dentistry has shown substantial efficacy.¹ Silver diamine fluoride is an inexpensive topical medicament used extensively in other countries to treat dental caries across the age spectrum. No other intervention approaches the ease of application and efficacy. Multiple randomized clinical trials — with hundreds of patients each — support its use for caries treatment, thus substantiating an intervention that addresses an unmet need in American dentistry. In August 2014, the Food and Drug Administration (FDA) cleared the first silver diamine fluoride product for market, and as of April 2015, that product is available.

Since its approval in Japan more than 80 years ago,² more than 2 million containers have been sold. The silver acts as an antimicrobial, the fluoride promotes remineralization and the ammonia stabilizes high concentrations in solution.³

Because silver diamine fluoride is new to American dentistry and dental education, there is a need for a standardized guideline, protocol and consent. The University of California, San Francisco, School of Dentistry paradigm shift committee assembled a subcommittee with the following goals:

- Use available evidence to develop a list of clinical indications.
- Define a protocol that maximized safety and efficacy and minimized inadvertent staining of clinical facilities.

- Build an informed consent document at the eighth-grade reading level.

We conducted a systematic review, inquired of authors of published clinical and in vitro studies about details and considerations in their protocols and consulted experts in cariology and materials chemistry where evidence was lacking. The work of this committee resulted in the adoption of silver diamine fluoride use in the UCSF student clinics.

Methods

A literature review was designed by a medical librarian to search PubMed and the International Association of Dental Research abstract archive with the following search terms: “33040-28-7” OR “1Z00ZK3E66” OR “silver diamine fluoride” OR “silver fluoride” OR “silver diamine fluoride” OR “diammine silver fluoride” OR “ammonical silver fluoride” OR “ammoniacal silver fluoride”. Differences in nomenclature have led to confusion around this material. Another review was completed with the terms “dental” OR “caries” AND “silver nitrate” AND “clinical.”

Material

Silver diamine fluoride (38% w/v $\text{Ag}(\text{NH}_3)_2\text{F}$, 30% w/w) is a colorless topical agent comprised of 24.4-28.8% (w/v) silver and 5.0-5.9% fluoride at pH 10,⁴ and marketed as Advantage Arrest by Elevate Oral Care LLC (West Palm Beach, Fla.). Other companies may market silver diamine fluoride in the future following determination of substantial equivalence and FDA clearance.

Mechanisms

Silver diamine fluoride is used for caries arrest and treatment of dentin hypersensitivity. In the treatment of exposed sensitive dentin surfaces,

topical application results in the development of a squamous layer on the exposed dentin, partially plugging the dentinal tubules.⁵ High concentration aqueous silver has been long known to form this protective layer.⁶ Decreased sensitivity in treated patients^{7,8} is consistent with the hydrodynamic theory of dentin hypersensitivity.⁹

Dental caries is a complex progression involving dietary sugars, bacterial metabolism, demineralization and organic degradation. The collagenous organic matrix is

Silver diamine fluoride outperforms other anticaries medicaments in killing cariogenic bacteria in dentinal tubules.

exposed once a dentin surface is demineralized and destroyed by native and bacterial proteases to enable a lesion to enlarge.¹⁰ Upon application of silver diamine fluoride to a decayed surface, the squamous layer of silver protein conjugates forms, increasing resistance to acid dissolution and enzymatic digestion.¹¹ Hydroxyapatite and fluorapatite form on the exposed organic matrix, along with the presence of silver chloride and metallic silver.⁵ The treated lesion increases in mineral density and hardness while the lesion depth decreases.⁵ Meanwhile, silver diamine fluoride specifically inhibits the proteins that break down the exposed dentin organic matrix: matrix metalloproteinases,¹¹ cathepsins¹² and bacterial collagenases.⁵ Silver

ions act directly against bacteria in lesions by breaking membranes, denaturing proteins and inhibiting DNA replication.^{13,14} Ionic silver deactivates nearly any macromolecule. Silver diamine fluoride outperforms other anticaries medicaments in killing cariogenic bacteria in dentinal tubules.¹⁵

Silver and fluoride ions penetrate ~25 microns into enamel¹⁶ and 50-200 microns into dentin.¹⁷ Fluoride promotes remineralization, and silver is available for antimicrobial action upon release by re-acidification.¹⁸ Silver diamine fluoride arrested lesions are 150 microns thick.¹⁹

Artificial lesions treated with silver diamine fluoride are resistant to biofilm formation and further cavity formation, presumably due to remnant ionic silver.^{20,21} More silver and fluoride is deposited in demineralized than nondemineralized dentin. Correspondingly, treated demineralized dentin is more resistant to caries bacteria than treated sound dentin.²² When bacteria killed by silver ions are added to living bacteria, the silver is re-activated so that effectively the dead bacteria kill the living bacteria in a “zombie effect.”²³ This reservoir effect helps explain why silver deposited on bacteria and dentin proteins within a cavity has sustained antimicrobial effects.

Clinical Evidence

Silver Nitrate Plus Fluoride Varnish

Before the FDA cleared silver diamine fluoride, some U.S. dentists sequentially applied silver nitrate then fluoride varnish to dentinal decay as the only available noninvasive option for caries treatment. Duffin rediscovered silver nitrate from the early literature,²⁴ which had been lost

to modern cariology. Surprisingly, there is no mention of silver nitrate in either of the American Dental Association Council on Scientific Affairs reports on *Nonfluoride Caries-Preventive Agents*²⁵ or *Managing Xerostomia and Salivary Gland Hypofunction*,²⁶ and it is not part of standard dental school curricula. Case series of carious lesions arrested by silver nitrate date to the 1800s. For example, in 1891, 87 of 142 treated lesions were arrested.²⁷ Percy Howe, DDS, then director of the Forsyth Institute in Boston, added ammonia to silver nitrate, making it more stable and effective as an antimicrobial for application to any infected tooth structure from early cavitated lesions to infected root canals.²⁸ Duffin added the application of fluoride varnish following silver nitrate, simulating silver diamine fluoride. While his clinic doubled in patients, cases needing general anesthesia disappeared. His review of randomly selected charts showed only seven of 578 treated lesions progressed within two and a half years to the point that extractions were needed.²⁴ Thus, with the exception of Duffin's and one other report, attention to silver nitrate largely disappeared by the 1950s. The lore is that use and teaching of this intervention were lost with the introduction of effective local anesthetic to enable painless restorations and fluoride for caries prevention. Because no high-quality clinical trials have been performed, we did not include the silver nitrate plus fluoride varnish regimen in our recommendation.

Silver Diamine Fluoride

We found nine published randomized clinical trials evaluating silver diamine fluoride for caries arrest and/or prevention of at least one year in duration. These

studies each involved hundreds of children aged 3 to 9 or adults aged 60 to 89 (FIGURES 1 and 2). Most participants had low (< 0.3 ppm) fluoride in the environmental water and reported using fluoride toothpaste (e.g., 73 percent).²⁹ Silver diamine fluoride was applied with cotton isolation. Lesions were detected with mirror and explorer only. All studies were registered and met the Consolidated Standards of Reporting Trials requirements. Clinical cases and studies not meeting these criteria can be found elsewhere.³⁰

When stannous fluoride was used to activate color change, a break in the black color within a lesion at six months was highly sensitive and specific for active caries.

Caries arrest increased dramatically after reapplication from one year posttreatment³¹⁻³³ to one and a half years,^{31,34} and increasingly to two to three years (FIGURE 1).^{29,31,35} Single application without repeat lost effect over time in the elderly.³² Twice per year application resulted in more arrest than once per year.^{31,35} Twelve percent silver diamine fluoride was markedly less effective.³²

Darkening of the entire lesion indicated success at follow-up and is suggested to facilitate diagnosis of caries arrest status by nondentists. A longitudinal study reported that color activation of silver diamine fluoride with 10% stannous fluoride resulted in less first molar caries.³⁶ Tea extract was used in one group to activate color change for improved follow-up diagnosis; no differences

in arrest were seen.³² Indeed, when stannous fluoride was used to activate color change, a break in the black color within a lesion at six months was highly sensitive and specific for active caries.³⁷

Silver diamine fluoride greatly outperformed fluoride varnish for caries arrest²⁹ and was equivalent or better than glass ionomer cement (GIC) (FIGURE 1).^{31,33} The addition of semiannual intensive oral health education with the application of silver diamine fluoride in the elderly increased the arrest of root caries (FIGURE 1).³⁸

Caries Prevention

When silver diamine fluoride was applied only to carious lesions, impressive prevention was seen for other tooth surfaces.^{29,35} Fluoride-releasing GIC can have this effect but it is limited to surfaces adjacent to the treated surface and of short duration. Direct application to healthy surfaces in children also helps prevent caries (FIGURE 2).^{29,35,39} Two studies show great difference in the level of prevention in the elderly;^{38,40} the difference is hard to reconcile. As seen for arrest, prevention is less after one year without repeat application.⁴¹

Annual application of silver diamine fluoride prevented many more carious lesions than four-times-per-year fluoride varnish in both children²⁹ and the elderly.⁴⁰ Prevention was roughly equivalent to twice-per-year varnish in one study (FIGURE 2).³⁹ The addition of semiannual intensive oral health education in a study of the elderly increased prevention.³⁸ Although many fell out, GIC or resin sealants outperformed silver diamine fluoride in preventing caries in the first molars of children,^{39,41} though the cost was ~20 times more.

Ongoing Trials

Unpublished reports of clinical studies unanimously confirm better caries arrest and/or prevention by silver diamine fluoride over control or other materials. A one-year report of a study of the elderly demonstrated that the addition of a saturated solution of potassium iodide (SSKI) to decrease discoloration did not significantly alter caries arrest or prevention.⁴² This was confirmed in the two-year examinations (personal communication, Edward Lo). A one-year report of a study in children showed that the application once per week for three consecutive weeks, once per year, was more effective than that of single annual application.⁴³ Other studies have recently begun to evaluate the ability of silver diamine fluoride to arrest interproximal carious lesions, to compare the relative efficacy of silver diamine fluoride to the combination of silver nitrate plus fluoride varnish and to compare the effects on populations with or without access to fluoridated water. Final reports from these studies will follow in the coming years.

Recommendations From the Literature on Clinical Efficacy

These studies show that 38% silver diamine fluoride is effective and efficient in arresting and preventing carious lesions. Application only to lesions appears to be similarly effective in preventing cavities in other teeth and surfaces as applying directly. Single application appears insufficient for sustained effects, while annual re-application results in remarkable success, and even greater effects with semi-annual application. From these data, we recommend twice-per-year application, only to carious lesions without excavation, for at least the first two years.

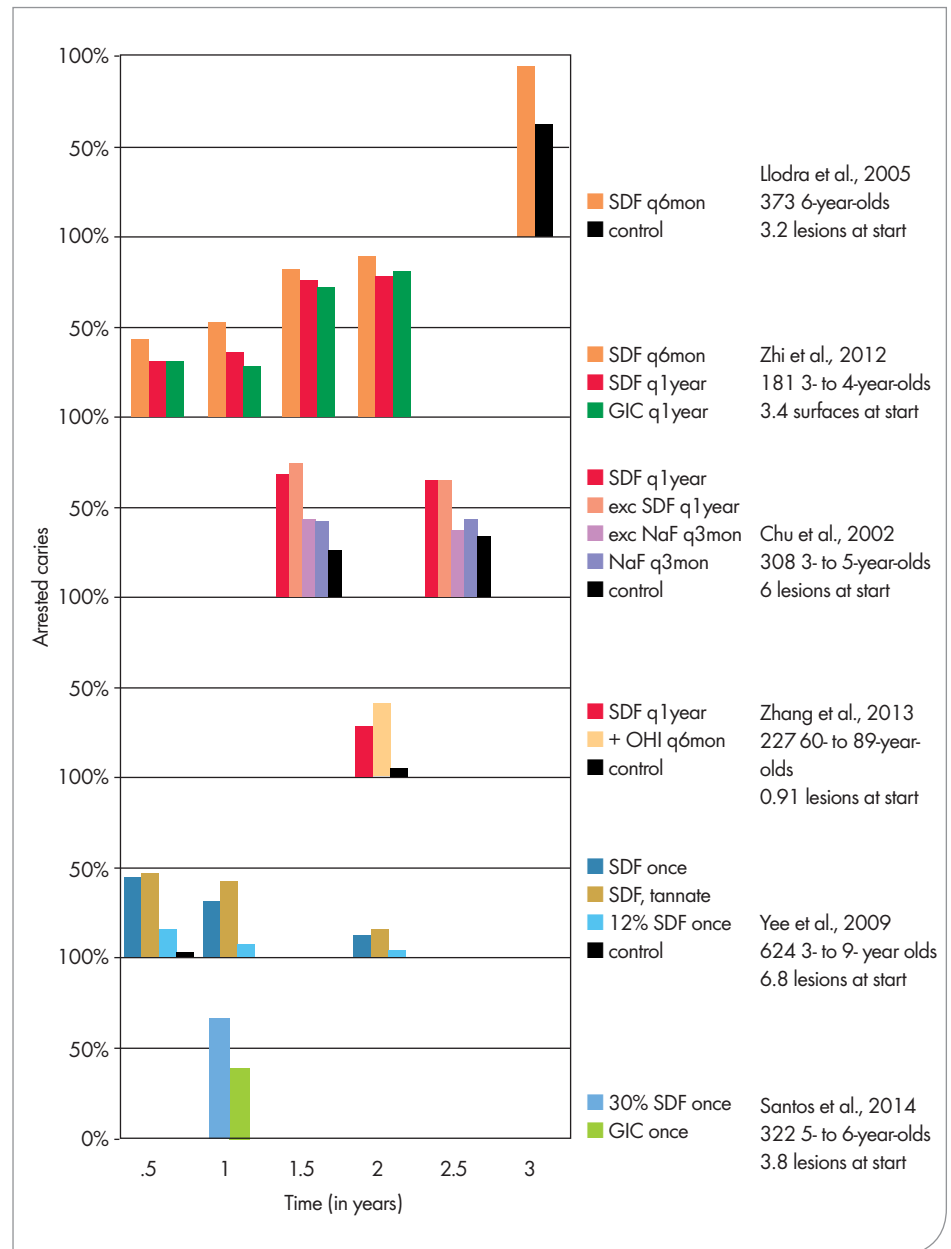


FIGURE 1. Graphic summary of randomized controlled trials demonstrating caries arrest after topical treatment with 38% silver diamine fluoride (SDF). Studies are arranged vertically by frequency of silver diamine fluoride application. Caries arrest is defined as the fraction of initially active carious lesions that became inactive and firm to a dental explorer. SDF (38% unless noted otherwise); q6mon, every six months; q1year, every year; q3mon, every three months; GIC, glass ionomer cement; NaF, 5% sodium fluoride varnish; + OHI q6mon, SDF every year and oral hygiene instructions every six months.

For any patient with active caries, we recommend considering replacement of fluoride varnish as the primary means to prevent new lesions, with application of silver diamine fluoride to the active lesions only. For patients without access

to both sealants and monitoring, silver diamine fluoride is the agent of choice for prevention of caries in permanent molars — particularly as there is no margin to leak and thereby facilitate deep caries and it does not stain sound enamel.

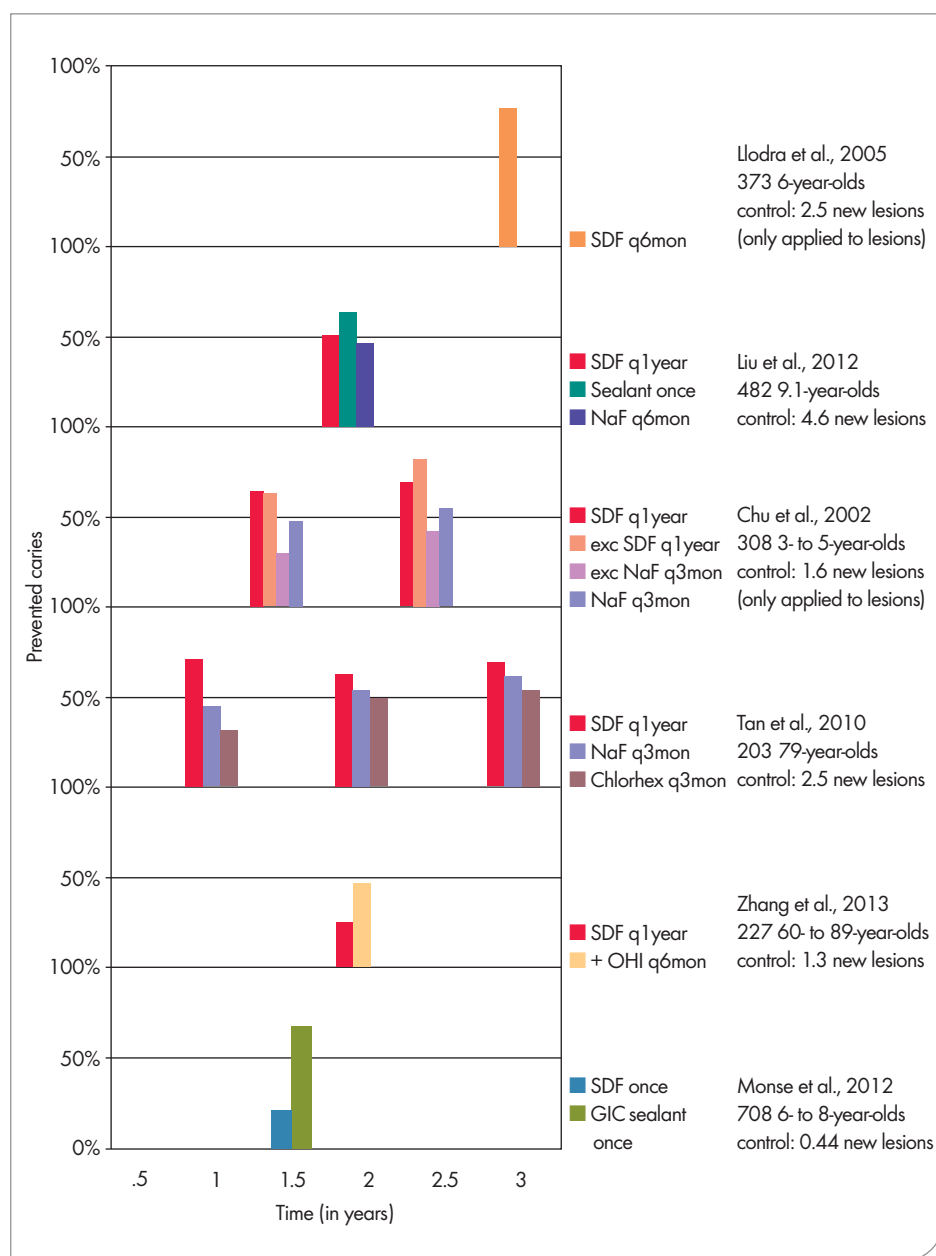


FIGURE 2. Graphic summary of randomized controlled trials demonstrating caries prevention after topical treatment of carious lesions with 38% silver diamine fluoride. Prevented caries is defined as the fraction of new carious lesions in treatment groups as compared to those in the placebo or no treatment control group. Chlorhex, 1% chlorhexidine varnish.

Longer studies are needed to determine whether caries arrest and prevention can be maintained with decreased application after two to three years, and whether more frequent use would enhance efficacy. Traditional or

nontraditional restorative approaches, such as the atraumatic restorative technique (ART)⁴⁴ and Hall crowns,⁴⁵ should be performed as dictated by the response of the patient, disease progression and the nature of individual lesions.

Safety

Maximum Dose and Safety Margin

The margin of safety for dosing is of paramount concern. In gaining clearance from the FDA, female and male rat and mouse studies were conducted to determine the lethal dose (LD50) of silver diamine fluoride by oral and subcutaneous administration. Average LD50 by oral administration was 520 mg/kg and by subcutaneous administration was 380 mg/kg. The subcutaneous route is taken here as a worst-case scenario. One drop (25 μ L) is ample material to treat five teeth and contains 9.5 mg silver diamine fluoride. Assuming the smallest child with caries would be in the range of 10 kg, the dose would be 0.95 mg/kg child. Thus, the relative safety margin of using an entire drop on a 10 kg child is 380 mg/kg LD50/0.95 mg/kg dose = four-hundredfold safety margin. The actual dose is likely to be much smaller, for example 2.37 mg total for three teeth was the largest dose measured in six patients.⁴⁶ The most frequent application monitored in a clinical trial was weekly for three weeks, annually.⁴³ Thus, we set our recommended limit as one drop (25 μ L) per 10 kg per treatment visit, with weekly intervals at most. This dose is commensurate with the Environmental Protection Agency's (EPA) allowable short-term exposure of 1.142 mg silver per liter of drinking water for one to 10 days (Agency for Toxic Substances and Disease Registry, ATSDR, 1990).

Cumulative exposure from lower-level acute or chronic silver intake has no real physiologic disease importance, but the bluing of skin in argyria should obviously be avoided. The EPA set the lifetime exposure conservatively at 1 gm to safely avoid argyria. The highest applied dose for three teeth measured in the pharmacokinetic study, 2.37 mg, would enable > 400 applications.⁴⁶ Silver

nitrate (typically a 25% solution) has been used for more than 100 years in the U.S. without incident, including acceptance by the ADA, and in other countries for arresting dental caries.³

Adverse Effects

Not a single adverse event has been reported to the Japanese authorities since they approved silver diamine fluoride (Saforide, Toyo Seiyaku Kasei Co. Ltd., Osaka, Japan) more than 80 years ago.⁴⁷ The manufacturer estimates that more than 2 million multi-use containers have been sold, including > 41,000 units in each of the last three reporting years.

In the nine randomized clinical trials in which silver diamine fluoride was applied to multiple teeth to arrest or prevent dental caries, the only side effect noted was for three of 1,493 children or elderly patients monitored for one to three years who experienced “a small, mildly painful white lesion in the mucosa, which disappeared at 48 [hours] without treatment.”^{29,31-33,35,38,40,41,48} The occurrence of reversible localized changes to the oral mucosa was predicted in the first reports of longitudinal studies.⁴⁹ No adverse pulpal response was observed.

Gingival responses have been minimal. In a pharmacokinetic study of silver diamine fluoride application to three teeth in each of six 48- to 82-year-olds, no erythema, bleeding, white changes, ulceration or pigmentation was found after 24 hours. Serum fluoride hardly went up from baseline, while serum silver increased about tenfold and stayed high past the four hours of measurement.⁴⁶ In a two-site hypersensitivity trial of 126 patients in Peru, at baseline 9 percent of patients presented redness scores of 2 (1 being normal, 2 being mild to moderate redness and 3 being severe); and after one day, 13 percent in silver diamine fluoride treated patients versus 4 percent

in controls. All redness was gone at seven days. Meanwhile, gingival index improved slightly in silver diamine fluoride treated patients.⁷ Nonetheless, gingival contact should be minimized. In our experience, it has been adequate to coat the nearby gingiva with petroleum jelly, use the smallest available microsponge and dab the side of the dappen dish to remove excess liquid before application.

Concerns for fluoride safety are most relevant to chronic exposure,⁵⁰ whereas this is an acute exposure. Chronically high systemic fluoride results in dental

At least for children, many parents have seen the color changes as a positive indication that the treatment was effective.

fluorosis. The ubiquitous use of fluoride-based gas in general anesthetics has shown that the first acute response is transient renal holding, and is rare.⁵¹ Concerns have been raised about poorly controlled silver diamine fluoride concentrations⁵² and fluorosis appearing in treated rats.⁵³ However, silver and fluoride levels are closely monitored for the U.S. product, and the Health Department of Western Australia conducted a study that found no evidence of fluorosis resulting from long-term proper use of silver diamine fluoride.⁵⁴ Therefore, we have concluded that the development of fluorosis after application of the U.S.-approved product is not a clinically significant risk.

Silver allergy is a contraindication. Relative contraindications include any significant desquamative gingivitis or

mucositis that disrupts the protective barrier formed by stratified squamous epithelium. Increased absorption and pain would be expected with contact. Heightened caution and use of a protective gingival coating may suffice.

A saturated solution of potassium iodide (SSKI) is contraindicated in pregnant women and during the first six months of breastfeeding because of the concern of overloading the developing thyroid with iodide; thyroid specialists suggested a pregnancy test prior to use in women of childbearing age uncertain of their status.

Nonmedical Side Effects

Silver diamine fluoride darkens carious lesions. At least for children, many parents have seen the color changes as a positive indication that the treatment was effective.²⁹ Application of an SSKI immediately following silver diamine fluoride treatment is thought to decrease staining (patent US6461161). This is an off-label use; potassium iodide is approved as an over-the-counter drug to facilitate mucus release to breathe more easily with chronic lung problems and to protect the thyroid from radioactive iodine in radiation emergencies. In our clinical experience, SSKI helps but does not dramatically effect stain; arrested lesions normally darken. Most stain remains at the dentin-enamel or cementum-enamel junction. However, SSKI maintains resistance to biofilm formation or activity in laboratory studies.²⁰ Also, SSKI maintained caries arrest efficacy in the early results of an ongoing clinical trial.⁴² Meanwhile, silver diamine fluoride-treated lesions can also be covered with GIC or composite (see below for discussion on bonding).

Patients note a transient metallic or bitter taste. In our experience, with judicious use, the taste and texture

response is more favorable than the response to fluoride varnish.

Even a small amount of silver diamine fluoride can cause a “temporary tattoo” to the skin (on the patient or provider), like a silver nitrate stain or henna tattoo, and does no harm. Stain on the skin resolves with the natural exfoliation of skin in two to 14 days. Universal precautions prevent most exposures. Long-term mucosal stain, local argyria akin to an amalgam tattoo, has been observed when applying silver nitrate to intraoral wounds; we anticipate similar stains with submucosal exposure to silver diamine fluoride.

Silver diamine fluoride stains clinic surfaces and clothes. The stain does not come out once it sets. Spills should be cleaned up immediately with copious water, ethanol or bleach. High pH solvents such as ammonia may be more successful. Secondary containers and plastic liners for surfaces are adequate preventives.

Effects on Bonding

Using a contemporary bonding system, silver diamine fluoride had no effect on composite bonding to noncarious dentin using either self-etch or full-etch systems.⁵⁵ In one study, simply rinsing after silver diamine fluoride application avoided a 50 percent decrease in bond strength for GIC.⁵⁶ In another study, increased dentin bond strength to GIC was observed.⁵⁷ Silver diamine fluoride decreased dentin bonding strength of resin-based crown cement by approximately one-third.⁵⁸ Thus, rinsing will suffice for direct restorations, while excavation of the silver diamine fluoride-treated superficial dentin is appropriate for cementing crowns.

Indications

Countless patients would benefit from conservative treatment of nonsymptomatic active carious lesions. We discuss the following indications.

First, extreme caries risk is defined as patients with salivary dysfunction, usually secondary to cancer treatment, Sjogren’s syndrome, polypharmacy, aging or methamphetamine abuse. For these patients, frequent prevention visits and traditional restorations fail to stop disease progression. Similar disease recurrence occurs in severe early childhood caries.

Second, some patients cannot tolerate standard treatment for medical or psychological reasons. These include the preoperative child, the frail elderly, those with severe cognitive or physical

Countless patients would benefit from conservative treatment of nonsymptomatic active carious lesions.

disabilities and those with dental phobias. Various forms of immunocompromise mean that these same patients have a much higher risk of systemic infection arising from untreated dental caries. Many only receive restorative care with general anesthesia or sedation and others are not good candidates for general anesthesia due to frailty or another medical complexity. The Centers for Disease Control and Prevention (CDC) estimates 1.4 million people in the U.S. live in nursing homes and 1.2 million live in hospice.⁵⁹ These individuals tend to have medical, behavioral, physical and financial limitations that beg a reasonable option.

Third, some patients have more lesions than can be treated in one visit, such that new lesions arise or existing lesions become symptomatic while

awaiting completion of treatment. This is particularly relevant to the dental school setting where treatment is slow. American dentistry has been desperately lacking an efficient instrument to be used at the diagnostic visit to provide a step toward controlling the disease.

Fourth, some lesions are just difficult to treat. Recurrent caries at a crown margin, root caries in a furcation or the occlusal of a partially erupted wisdom tooth pose a challenge to access, isolation and cleansability necessary for restorative success.

Following the above considerations, we developed four indications for treatment of dental caries with silver diamine fluoride:

1. Extreme caries risk (xerostomia or severe early childhood caries).
2. Treatment challenged by behavioral or medical management.
3. Patients with carious lesions that may not all be treated in one visit.
4. Difficult to treat dental carious lesions.

Finally, these indications are for our school clinics. They do not address access to care. The U.S. Department of Health and Human Services estimates 108 million Americans are without dental insurance, and there are 4,230 shortage areas with 49 million people without access to a dental health professional.⁶⁰ Unlike fillings, failure of silver diamine fluoride treatment does not appear to create an environment that promotes caries, and thus needs to be monitored. Thus, a final important indication is:

5. Patients without access to dental care.

Clinical Application

We considered practical strategies to maximize safety and effectiveness in the design of a clinical protocol for the UCSF dental clinics (**FIGURE 3**).

The key factor is repeat application

Silver Diamine Fluoride (SDF) UCSF Protocol for Arresting Dental Carious Lesions or Treating Tooth Sensitivity

Material: Advantage Silver Arrest (38% SDF, purified water) from Elevate Oral Care.
Shelf life: three years unopened. Do not refrigerate. Avoid freezing or extreme heat.

Indications:

1. Extreme caries risk (xerostomia or severe early childhood caries).
2. Treatment challenged by behavioral or medical management.
3. Patients with carious lesions that may not all be treated in one visit.
4. Difficult to treat dental carious lesions.
5. Patients without access to dental care.

Maximum dose: 25 μ L (1 drop) / 10kg per treatment visit.

SDF Contraindication: Silver allergy.

SDF Relative Contraindications: Ulcerative gingivitis, stomatitis.

SSKI Contraindications: Pregnancy, breastfeeding.

Considerations:

- Decayed dentin will darken as the caries lesions arrest. Most will be dark brown or black.
- SDF can stain the skin, which will clear in two to three weeks without treatment.
- SDF can permanently stain operatory surfaces and clothes.
- A control restoration (e.g., GI via ART or other material) may be considered after SDF treatment.
- Saturated solution of potassium iodide (SSKI, Lugol's Solution, various sources) can be used after SDF to decrease color changes.
- Re-application is usually recommended, biannually until the cavity is restored or arrested or the tooth exfoliates.

Procedure:

1. Plastic-lined cover for counter, plastic-lined bib for patient.
2. Standard personal protective equipment (PPE) for provider and patient.
3. One drop of SDF into the deep end of a plastic dappen dish (also obtain one drop of SSKI in a separate dappen dish if selected).
4. Remove bulk saliva with saliva ejector.
5. Isolate tongue and cheek from affected teeth with 2-inch by 2-inch gauze or cotton rolls.
6. If near the gingiva, consider applying petroleum jelly with a cotton applicator for safety.
7. Dry affected tooth surfaces with triple syringe or if not feasible dry with cotton.
8. Bend microsponge, immerse into SDF, remove excess on side of dappen dish.
9. Apply directly onto the affected tooth surface(s) with microsponge.
10. Allow SDF to absorb for up to one minute if reasonable, then remove excess with gauze or cotton roll.
(If using SSKI, apply with a different microsponge. Repeat one to three times until no further white precipitates are observed.
Wait five to 10 seconds between applications. Remove excess with cotton.)
11. Rinse with water.
12. Place gloves, cotton and microbrushes into plastic waste bags.

FIGURE 3. Clinical protocol for the UCSF dental clinics.

over multiple years. We believe that dryness of the lesion during application is also important. Isolation with gauze and/or cotton rolls is sufficient, while air drying prior to application is thought to improve effectiveness. Allowing one to three minutes for the silver diamine fluoride to soak into and react with a lesion is thought to effect success.

Allowing only a few seconds to soak in due to the cooperation limits of very young patients commonly results in arrest. Application time in clinical studies does not correlate to outcome. However, our committee decided to be cautious in our recommendations for initial use. Longer absorption time also decreases concerns about removing silver

diamine fluoride with a posttreatment rinse. Removing any excess material with the same cotton used to isolate is routine to minimize systemic absorption.

Many clinicians place silver diamine fluoride at the diagnostic visit, then at one and/or three-month follow ups, then at semiannual recall visits (six, 12, 18, 24 months). Whether application needs

to continue after two or three years to maintain caries arrest is not known. Another approach is simply to substitute silver diamine fluoride for any application of fluoride varnish to a patient with untreated carious lesions. Increased frequency with higher disease burden follows the caries management by risk assessment (CAMBRA) principles.⁶¹ It is relevant to take photographs to track lesions over time.

Efforts to improve the penetration of silver diamine fluoride into affected dentin by chemical cavity preparation have not been studied but are being explored clinically. Pretreatment with ethylenediaminetetraacetic acid (EDTA) to remove superficial hydroxyapatite in affected dentin may open the dentinal tubules to further silver diamine fluoride penetration. Pretreatment with hypochlorite (bleach) may help breakdown bacteria and exposed dentin proteins, but this may be redundant to the action of the silver. Hypochlorite to decrease discoloration after silver diamine fluoride treatment is not recommended, as the color comes from silver that cannot be broken down like organic chromophores and might break down dentin proteins stabilized against the effects of bacteria and acid by interactions with silver.

Experience with the combination of silver nitrate plus fluoride varnish (see above) has many practitioners asking about a topical varnish after silver diamine fluoride placement to prevent silver diamine fluoride taste and keep the silver diamine fluoride in the lesion. We see no evidence that varnish would help achieve either goal. Varnish does not seal. Rather, allowing more time for residence and diffusion of silver diamine fluoride to react with and dry into the lesion is more likely to improve effectiveness. Also, in our experience, silver diamine fluoride results in less aversive taste and texture responses than to fluoride varnish.

Decreased darkening of lesions in the esthetic zone improves acceptance. SSKI is an option if the patient is not pregnant, though significant darkening should still be expected. SSKI and silver diamine fluoride are not to be combined prior to application — SSKI can be placed after drying the silver diamine fluoride-treated tooth. Silver diamine fluoride does not prevent restoration of a lesion, thus it does not prevent esthetic options. While silver diamine fluoride has been shown to be more effective than ART or interim restorative treatment

In our experience, silver diamine fluoride results in less aversive taste and texture responses than to fluoride varnish.

(IRT),³³ the two are compatible and can be combined across one or more visits.

The California Business and Professions Code permits dental hygienists and assistants to apply silver diamine fluoride for the control of caries because they are topical fluorides (Section 1910.(b)). Physicians, nurses and their assistants are permitted to apply fluorides in California and in many other states and federal programs. The recent decision of the Oregon Dental Board to allow dental hygienists and assistants to place silver diamine fluoride under existing rules for topical fluoride medicaments sets a precedent. Dental hygienists and assistants in Oregon were barred from providing silver nitrate in a previous decision. All providers need to be trained. Applications should be tracked if applied to the same patient by multiple clinics.

Documentation and Billing

A new code, D1354, for “interim caries arresting medication application” was approved by the Code on Dental Procedures and Nomenclature (CDT) Code Maintenance Commission for 2016. The code definition is “Conservative treatment of an active, nonsymptomatic carious lesion by topical application of a caries arresting or inhibiting medicament and without mechanical removal of sound tooth structure.” The CDT Code is the U.S. HIPAA standard code set and is required for billing. The Commission includes representatives from the major insurers, Medicaid, ADA, AGD and specialty organizations. Insurers are in the process of evaluating coverage for this treatment.

Legal Considerations

Silver diamine fluoride is cleared by the FDA for marketing as a Class II medical device to treat tooth sensitivity. We are discussing off-label use as a drug to treat and prevent dental caries. This is a parallel situation to fluoride varnish, which has the same device clearance but is ubiquitously used off label by dentists and physicians as a drug to prevent caries. The same public health dentists who achieved the FDA device clearance are now applying for a dental caries indication. However, this is a more complicated process, normally only carried out by large pharmaceutical companies, and is likely to take longer.

Consent

Because silver diamine fluoride is new in the U.S., it is important to communicate effectively. In the UCSF clinics, we are using a special consent form (**FIGURE 4**) as a way to inform patients, parents and caregivers, and

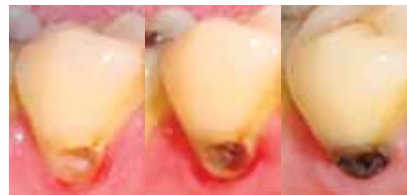UCSF Dental Center Informed Consent for Silver Diamine Fluoride

Facts for consideration:

- Silver diamine fluoride (SDF) is an antibiotic liquid. We use SDF on cavities to help stop tooth decay. We also use it to treat tooth sensitivity. SDF application every six to 12 months is necessary.
- The procedure: 1. Dry the affected area. 2. Place a small amount of SDF on the affected area. 3. Allow SDF to dry for one minute. 4. Rinse.
- **Treatment with SDF does not eliminate the need for dental fillings or crowns to repair function or esthetics. Additional procedures will incur a separate fee.**
- I should not be treated with SDF if: 1. I am allergic to silver. 2. There are painful sores or raw areas on my gums (i.e., ulcerative gingivitis) or anywhere in my mouth (i.e., stomatitis).

Benefits of receiving SDF:

- SDF can help stop tooth decay.
- SDF can help relieve sensitivity.



Risks related to SDF include, but are not limited to:

- **The affected area will stain black permanently.** Healthy tooth structure will not stain. Stained tooth structure can be replaced with a filling or a crown.
- Tooth-colored fillings and crowns may discolor if SDF is applied to them. Color changes on the surface can normally be polished off. The edge between a tooth and filling may keep the color.
- If accidentally applied to the skin or gums, a brown or white stain may appear that causes no harm, cannot be washed off and will disappear in one to three weeks.
- You may notice a metallic taste. This will go away rapidly.
- If tooth decay is not arrested, the decay will progress. In that case the tooth will require further treatment, such as repeat SDF, a filling or crown, root canal treatment or extraction.
- These side effects may not include all of the possible situations reported by the manufacturer. If you notice other effects, please contact your dental provider.
- Every reasonable effort will be made to ensure the success of SDF treatment. There is a risk that the procedure will not stop the decay and no guarantee of success is granted or implied.

Alternatives to SDF, not limited to the following:

- No treatment, which may lead to continued deterioration of tooth structures and cosmetic appearance. Symptoms may increase in severity.
- Depending on the location and extent of the tooth decay, other treatment may include placement of fluoride varnish, a filling or crown, extraction or referral for advanced treatment modalities.

I CERTIFY THAT I HAVE READ AND FULLY UNDERSTAND THIS DOCUMENT AND ALL MY QUESTIONS WERE ANSWERED:

_____ (signature of patient) _____ (date)
 _____ (signature of witness) _____ (date)

FIGURE 4. UCSF special consent form.

to standardize procedures because we have so many inexperienced student clinicians. All practices have established procedures for consent and an extra form may not be needed in the community. The normal elements of informed consent

apply. We sought to ensure awareness of the expected change in color of the dentin as the decay arrests, likelihood of reapplication and contraindications in the presence of silver allergy and stomatitis. Note the importance of distinguishing

between allergy to nickel and other trace metals rather than silver allergy, which is rare. We used readability measurements to guide intelligibility and included a progressively discoloring lesion to show stain of a lesion but not healthy enamel.

Conclusion

Silver diamine fluoride is a safe, effective treatment for dental caries across the age spectrum. At UCSF, it is indicated for patients with extreme caries risk, those who cannot tolerate conventional care, patients who must be stabilized so they can be restored over time, patients who are medically compromised or too frail to be treated conventionally and those in disparity populations with little access to care.

Application twice per year outperforms all minimally invasive options including the atraumatic restorative technique — with which it is compatible but 20 times less expensive. It approaches the success of dental fillings after two or more years, and again, prevents future caries — while fillings do not. Silver diamine fluoride is more effective as a primary preventive than any other available material, with the exception of dental sealants, which are > 10 times more expensive and need to be monitored.

Saliva may play a role in caries arrest by silver diamine fluoride. Lower rates of arrest are seen in geriatric patients.³⁸ The elderly tend to have less abundant and less functional saliva, which generally explains their higher caries rate. In pediatric patients, higher rates of arrest are noted for buccal or lingual smooth surfaces and anterior teeth.³¹ These surfaces bathe more directly in saliva than others. It is surprising that silver chloride is the main precipitant in treated dentin, as chloride is not a common component of dentin or silver diamine fluoride, so may come from the saliva.

Traditional approaches often provide only temporary benefit, given the highest rates of recurrent caries are in patients with the worst disease burden. The advent of a treatment for nonsymptomatic caries not requiring general anesthesia or sedation addresses long-standing

concerns about the expense, danger and practical complexity of these services.

Experience suggests that dryness prior to application enhances effectiveness. Good patient management is still profoundly relevant to the very young and otherwise challenged patients, though this one-minute intervention is more tolerable than other options. Silver diamine fluoride can readily replace fluoride varnish for the prevention of caries in patients who have active caries. This as a powerful new tool in the fight against dental caries, particularly suited for those who suffer most from this disease.

Clinical evidence supports continued application one to two times per year until the tooth is restored or exfoliates, and otherwise perhaps indefinitely. Some treated lesions keep growing, particularly those in the inner third of the dentin. It is unclear what will happen if treatment is stopped after two to three years and research is needed. ■

ACKNOWLEDGMENT

The UCSF paradigm shift committee subcommittee on silver caries arrest included Sean Mong, DDS, EdD; Spomenka Djordjevic, DDS, MS; Paul Atkinson, DDS, PhD; George Taylor, DMD, MPH, DrPh; Natalie Heavilin, DDS; Ling Zhan, DDS, PhD; John Featherstone, PhD; Hellene Ellenikiotis, DDS; and Jeremy Horst, DDS, PhD. Thanks to Linda Milgrom for designing the PubMed search. Thanks to Chad Zillich, DDS, for help with the literature review. Thanks to study authors, particularly Edward Lo, BDS, MDS, PhD; Chun Hung Chu, BDS, MDS, PhD; and Geoff Knight, BDS, MSc, MBA, for helpful discussions.

REFERENCES

- Clarkson BH, Exterkate RAM. Noninvasive dentistry: A dream or reality? *Caries Res* 2015;49 suppl 1(1):11-17. doi:10.1159/000380887.
- Yamaga R, Yokomizo I. Arrestment of caries of deciduous teeth with diamine silver fluoride. *Dent Outlook* 1969;33:1007-1013.
- Rosenblatt A, Stamford TCM, Niederman R. Silver diamine fluoride: A caries "silver-fluoride bullet." *J Dent Res* 2009;88(2):116-125. doi:10.1177/0022034508329406.
- Mei ML, Chu CH, Lo ECM, Samaranyake LP. Fluoride and silver concentrations of silver diamine fluoride solutions for dental use. *Int J Paediatr Dent* 2013;23(4):279-285. doi:10.1111/ipd.12005.
- Mei ML, Ito L, Cao Y, Li QL, Lo ECM, Chu CH. Inhibitory effect of silver diamine fluoride on dentine demineralisation and collagen degradation. *J Dent* 2013;41(9):809-817.

- doi:10.1016/j.jdent.2013.06.009.
- Hill TJ, Arnold FA. The effect of silver nitrate in the prevention of dental caries. I. The effect of silver nitrate upon the decalcification of enamel. *J Dent Res* 1937;16:23-28.
- Castillo JL, Rivera S, Aparicio T, et al. The short-term effects of diamine silver fluoride on tooth sensitivity: A randomized controlled trial. *J Dent Res* 2011;90(2):203-208. doi:10.1177/0022034510388516.
- Craig GG, Knight GM, McIntyre JM. Clinical evaluation of diamine silver fluoride/potassium iodide as a dentine desensitizing agent. A pilot study. *Aust Dent J* 2012;57(3):308-311. doi:10.1111/j.1834-7819.2012.01700.x.
- Markowitz K, Pashley DH. Discovering new treatments for sensitive teeth: The long path from biology to therapy. *J Oral Rehabil* 2008;35(4):300-315. doi:10.1111/j.1834-2842.2007.01798.x.
- Featherstone JDB. The continuum of dental caries — evidence for a dynamic disease process. *J Dent Res* 2004;83 Spec No C:C39-C42.
- Mei ML, Li QL, Chu CH, Yiu CKY, Lo ECM. The inhibitory effects of silver diamine fluoride at different concentrations on matrix metalloproteinases. *Dent Mater* 2012;28(8):903-908. doi:10.1016/j.dental.2012.04.011.
- Mei ML, Ito L, Cao Y, Li QL, Chu CH, Lo ECM. The inhibitory effects of silver diamine fluorides on cysteine cathepsins. *J Dent* 2014;42(3):329-335. doi:10.1016/j.jdent.2013.11.018.
- Klasen HJ. A Historical Review of the Use of Silver in the Treatment of Burns. II. Renewed Interest for Silver. 2000:131-138.
- Youravong N, Carlen A, Teanpaisan R, Dahlén G. Metal-ion susceptibility of oral bacterial species. *Left Appl Microbiol* 2011;53(3):324-328. doi:10.1111/j.1472-765X.2011.03110.x.
- Hamama HH, Yiu CK, Burrow MF. Effect of silver diamine fluoride and potassium iodide on residual bacteria in dentinal tubules. *Aust Dent J* 2015;60(1):80-87. doi:10.1111/adj.12276.
- Suzuki T, Nishida M, Sobue S, Moriwaki Y. Effects of diamine silver fluoride on tooth enamel. *J Osaka Univ Dent Sch* 1974;14:61-72.
- Chu CH, Lo ECM. Micro-hardness of dentin in primary teeth after topical fluoride applications. *J Dent* 2008;36(6):387-391. doi:10.1016/j.jdent.2008.02.013.
- Englander HR, James VE, Massler M. Histologic effects of silver nitrate of human dentin and pulp. *J Am Dent Assoc* 1958;57(5):621-630.
- Mei ML, Ito L, Cao Y, Lo ECM, Li QL, Chu CH. An ex vivo study of arrested primary teeth caries with silver diamine fluoride therapy. *J Dent* 2014;42(4):395-402. doi:10.1016/j.jdent.2013.12.007.
- Knight GM, McIntyre JM, Craig GG, Mulyani, Zilm PS, Gully NJ. Inability to form a biofilm of *Streptococcus mutans* on silver fluoride- and potassium iodide-treated demineralized dentin. *Quintessence Int* 2009;40(2):155-161.
- Knight GM, McIntyre JM, Craig GG, Mulyani, Zilm PS, Gully NJ. An in vitro model to measure the effect of a silver fluoride and potassium iodide treatment on the permeability of demineralized dentine to *Streptococcus mutans*. *Aust Dent J* 2005;50(4):242-245.
- Knight GM, McIntyre JM, Craig GG, Mulyani, Zilm PS, Gully NJ. Differences between normal and demineralized

- dentine pretreated with silver fluoride and potassium iodide after an in vitro challenge by *Streptococcus mutans*. *Aust Dent J* 2007;52(1):16-21.
23. Wakshlak RB-K, Pedahzur R, Avnir D. Antibacterial activity of silver-killed bacteria: the "zombies" effect. *Sci Rep* 2015;5:9555. doi:10.1038/srep09555.
24. Duffin S. Back to the future: The medical management of caries introduction. *J Calif Dent Assoc* 2012;40(11):852-858.
25. Rethman MP, Beltrán-Aguilar ED, Billings RJ, et al. Nonfluoride caries-preventive agents: Executive summary of evidence-based clinical recommendations. *J Am Dent Assoc* 2011;142(9):1065-1071.
26. Plemons JM, Al-Hashimi I, Marek CL. Managing xerostomia and salivary gland hypofunction. *J Am Dent Assoc* 2014;145(8):867-873. doi:10.14219/jada.2014.44.
27. Stebbins EA. What value has argenti nitras as a therapeutic agent in dentistry? *Int Dent J* 1891;12:661-670.
28. Howe PR. A method of sterilizing and at the same time impregnating with a metal affected dentinal tissue. *Dent Cosmos* 1917;59:891-904.
29. Chu CH, Lo ECM, Lin HC. Effectiveness of silver diamine fluoride and sodium fluoride varnish in arresting dentin caries in Chinese preschool children. *J Dent Res* 2002;81(11):767-770.
30. Shah S, Bhaskar V, Venkataraghavan K, Choudhary P, Ganesh M, Trivedi K. Efficacy of silver diamine fluoride as an antibacterial as well as antiplaque agent compared to fluoride varnish and acidulated phosphate fluoride gel: An in vivo study. *Indian J Dent Res* 2013;24(5):575-581. doi:10.4103/0970-9290.123374.
31. Zhi QH, Lo ECM, Lin HC. Randomized clinical trial on effectiveness of silver diamine fluoride and glass ionomer in arresting dentine caries in preschool children. *J Dent* 2012;40(11):962-967. doi:10.1016/j.jdent.2012.08.002.
32. Yee R, Holmgren C, Mulder J, Lama D, Walker D, van Palenstein Helderma W. Efficacy of silver diamine fluoride for arresting caries treatment. *J Dent Res* 2009;88(7):644-647. doi:10.1177/0022034509338671.
33. Santos Dos VE, de Vasconcelos FMN, Ribeiro AG, Rosenblatt A. Paradigm shift in the effective treatment of caries in schoolchildren at risk. *Int Dent J* 2012;62(1):47-51. doi:10.1111/j.1875-595X.2011.00088.x.
34. Lo EC, Chu CH, Lin HC. A community-based caries control program for preschool children using topical fluorides: 18-month results. *J Dent Res* 2001;80(12):2071-2074.
35. Llodra JC, Rodriguez A, Ferrer B, Menardia V, Ramos T, Morato M. Efficacy of silver diamine fluoride for caries reduction in primary teeth and first permanent molars of schoolchildren: 36-month clinical trial. *J Dent Res* 2005;84(8):721-724.
36. Green E. A clinical evaluation of two methods of caries prevention in newly erupted first permanent molars. *Aust Dent J* 1989;34(5):407-409.
37. Craig GG, Powell KR, Price CA. Clinical evaluation of a modified silver fluoride application technique designed to facilitate lesion assessment in outreach programs. *BMC Oral Health* 2013;13(1):73. doi:10.1186/1472-6831-13-73.
38. Zhang W, McGrath C, Lo ECM, Li JY. Silver diamine fluoride and education to prevent and arrest root caries among community-dwelling elders. *Caries Res* 2013;47(4):284-290. doi:10.1159/000346620.
39. Liu BY, Lo ECM, Chu CH, Lin HC. Randomized trial on fluorides and sealants for fissure caries prevention *J Dent Res* 2012;91(8):753-758. doi:10.1177/0022034512452278.
40. Tan HP, Lo ECM, Dyson JE, Luo Y, Corbet EF. A randomized trial on root caries prevention in elders. *J Dent Res* 2010;89(10):1086-1090. doi:10.1177/0022034510375825.
41. Monse B, Heinrich-Weltzien R, Mulder J, Holmgren C, van Palenstein Helderma WH. Caries preventive efficacy of silver diamine fluoride (SDF) and ART sealants in a school-based daily fluoride toothbrushing program in the Philippines. *BMC Oral Health* 2012;12(1):52. doi:10.1186/1472-6831-12-52.
42. Li R, Lo ECM, Chu CH, Liu BY. Preventing and arresting root caries through silver diamine fluoride applications. In: 2014. iadr.confex.com/iadr/14iags/webprogram/Paper189080.html.
43. Duangthip D, Lo ECM, Chu CH. Arrest of dentin caries in preschool children by topical fluorides. In: 2014. iadr.confex.com/iadr/14iags/webprogram/Paper189031.html.
44. Frencken JE, Pilot T, Songpaisan Y, Phantumvanit P. Atraumatic Restorative Treatment (ART): Rationale, Technique and Development. *J Public Health Dent* 1996;56(3):135-140. doi:10.1111/j.1752-7325.1996.tb02423.x.
45. Innes NP, Evans DJ, Stirrups DR. The Hall Technique: A randomized controlled clinical trial of a novel method of managing carious primary molars in general dental practice: Acceptability of the technique and outcomes at 23 months. *BMC Oral Health* 2007;7(1):18. doi:10.1186/1472-6831-7-18.
46. Vasquez E, Zegarra G, Chirinos E, et al. Short-term serum pharmacokinetics of diamine silver fluoride after oral application. *BMC Oral Health* 2012;12(1):60. doi:10.1186/1472-6831-12-60.
47. Chu CH, Lo ECM. Promoting caries arrest in children with silver diamine fluoride: A review. *Oral Health Prev Dent* 2008;6(4):315-321.
48. Liu Y, Zhai W, Du F. [Clinical observation of treatment of tooth hypersensitivity with silver ammonia fluoride and potassium nitrate solution]. *Zhonghua Kou Qiang Yi Xue Za Zhi*. 1995;30(6):352-354.
49. Yamaga R, Nishino M, Yoshida S, Yokomizo I. Diamine silver fluoride and its clinical application. *J Osaka Univ Dent Sch* 1972;12(1):1-20.
50. Milgrom P, Taves DM, Kim AS, Watson GE, Horst JA. Pharmacokinetics of fluoride in toddlers after application of 5% sodium fluoride dental varnish. *Pediatrics* 2014;134(3):e870-e874. doi:10.1542/peds.2013-3501.
51. Goldberg ME, Cantillo J, Larjani GE, Torjman M, Vekeman D, Schieren H. Sevoflurane versus isoflurane for maintenance of anesthesia: Are serum inorganic fluoride ion concentrations of concern? *Anesth Analg* 1996;82(6):1268-1272.
52. Gotjamanos T, Afonso F. Unacceptably high levels of fluoride in commercial preparations of silver fluoride. *Aust Dent J* 1997;42(1):52-53.
53. Gotjamanos T, Ma P. Potential of 4 percent silver fluoride to induce fluorosis in rats: Clinical implications. *Aust Dent J* 2000;45(3):187-192.
54. Neesham DC. Fluoride concentration in AgF and dental fluorosis. *Aust Dent J* 1997;42(4):268-269.
55. Quock RL, Barros JA, Yang SW, Patel SA. Effect of Silver Diamine Fluoride on Microtensile Bond Strength to Dentin. *Oper Dent* 2012;37(6):610-616. doi:10.2341/11-344-L.
56. Knight GM, McIntyre JM, Mulyani. The effect of silver fluoride and potassium iodide on the bond strength of auto cure glass ionomer cement to dentine. *Aust Dent J* 2006;51(1):42-45.
57. Yamaga M, Koide T, Hieda T. Adhesiveness of glass ionomer cement containing tannin-fluoride preparation (HY agent) to dentin – an evaluation of adding various ratios of HY agent and combination with application diamine silver fluoride. *Dent Mater J* 1993;12(1):36-44.
58. Soeno K, Taira Y, Matsumura H, Atsuta M. Effect of desensitizers on bond strength of adhesive luting agents to dentin. *J Oral Rehabil* 2001;28(12):1122-1128.
59. Centers for Disease Control and Prevention. Long-Term Care Services in the United States: 2013 Overview, table 4. www.cdc.gov/nchs/data/nsitcp/long_term_care_services_2013.pdf.
60. U.S. Department of Health and Human Services. Integration of Oral Health and Primary Care Practice. www.hrsa.gov/publichealth/clinical/oralhealth. Accessed June 5, 2015.
61. Featherstone JDB, Adair SM, Anderson MH, et al. Caries management by risk assessment: Consensus statement, April 2002. *J Calif Dent Assoc* 2003 Mar;31(3):257-69.

THE CORRESPONDING AUTHOR, Jeremy A. Horst, DDS, PhD, can be reached at jeremy.horst@ucsf.edu.